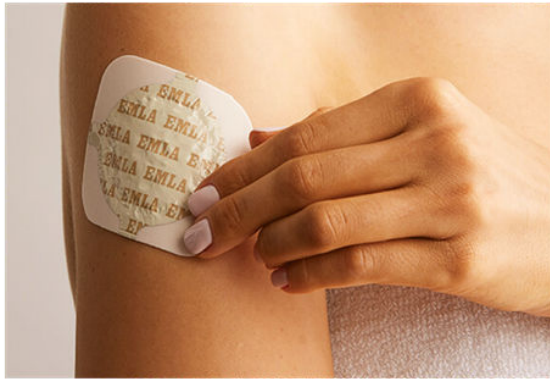

NEET PG PYQS 2024

Anesthesia

Topic: Local Anaesthetics

Q.1. Which of the following is true regarding the image provided?

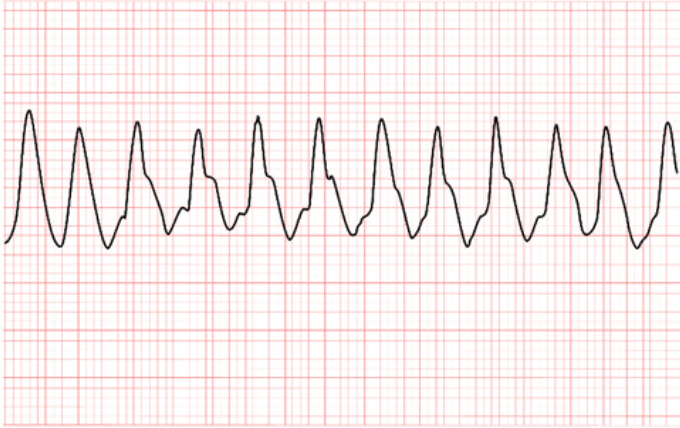


1. EMLA contains ropivacaine and lignocaine
2. EMLA can lead to hemoglobinemia.
3. EMLA contains 5% lignocaine
4. EMLA acts within 15 minutes.

Correct Answer: EMLA can lead to methemoglobinemia

Topic: Cardiopulmonary Cerebral Resuscitation

Q.2. A patient presents with no pulse, and the ECG shows the following rhythm. What is the next appropriate step?



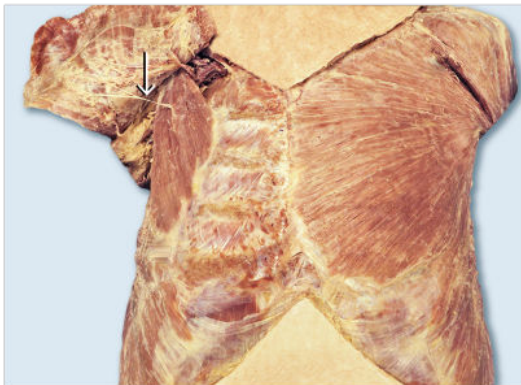
1. Defibrillate, check pulse and then perform CPR
2. Cardioversion
3. Defibrillate, perform CPR, and then check the pulse
4. Administer epinephrine

Correct Answer: Defibrillate, perform CPR, and then check the pulse

Anatomy

Topic: Neuro Anatomy

Q.3. Identify the arrow-marked nerve



1. Medial pectoral nerve
2. Lateral pectoral nerve
3. Long thoracic nerve
4. Thoracodorsal nerve

Correct Answer: Medial pectoral nerve

Topic: Lower Limb

Q.4. Behind the medial malleolus and in front of Achilles, which artery is present?

1. Posterior tibial artery
2. Peroneal artery
3. Anterior tibial artery
4. Dorsalis pedis artery

Correct Answer: posterior tibial artery

Topic: General Embryology

Q.5. The covering of an omphalocele is derived from which layer?

1. Amnion
2. Chorion
3. Mesoderm
4. Endoderm

Correct Answer: Amnion

Biochemistry

Topic: Enzymes

Q.6. A 13-year-old boy presents with jaundice, fatigue, muscle stiffness, tremors, behavioral changes, hepatosplenomegaly, and Kayser-Fleischer rings. Which test is definitive for the diagnosis?

1. Urinary copper
2. Serum ceruloplasmin
3. Hepatic parenchymal copper concentration
4. Genetic testing for ATP7B mutation

Correct Answer: Serum ceruloplasmin

Topic: Lipid Metabolism

Q.7. A patient presents with xanthomas on the Achilles tendon. Which of the following is the most likely diagnosis?

1. Familial hypercholesterolemia
2. Tangier disease
3. Familial hyperchylomicronemia
4. Type III hyperlipoproteinemia

Correct Answer: Familial hypercholesterolemia

Topic: Lipid Metabolism

Q.8. A patient with multiple tendon xanthomas is found to have a serum cholesterol level of 398 mg/dL and an LDL level of 220 mg/dL. What is the most likely defect?

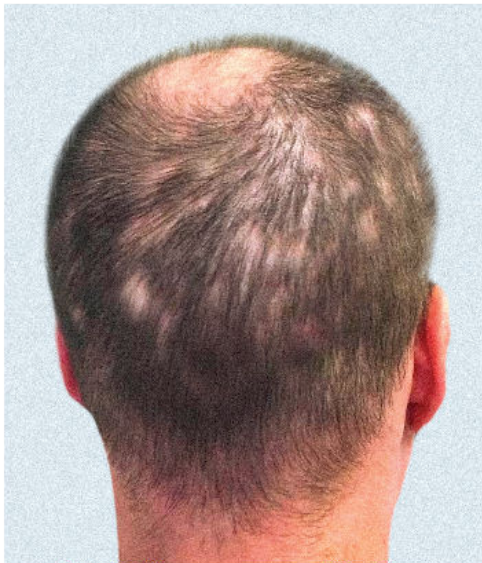
1. Lipoprotein lipase deficiency
2. LDL receptor defect
3. Defective Apo B-100
4. PCSK9 gain-of-function mutation

Correct Answer: LDL receptor defect

Dermatology

Topic: Sexually Transmitted Infections

Q.9. A 30-year-old patient presents with a history of flat lesions near the anal canal, rashes on the body, and hair loss that follows a particular pattern, as shown in the image. What is the diagnosis?

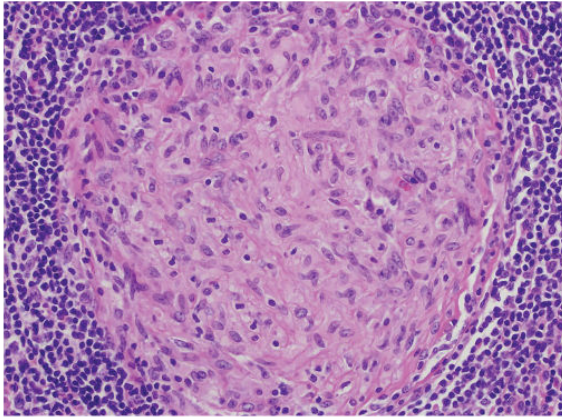


1. Trichotillomania
2. Alopecia areata
3. Secondary syphilis
4. Malassezia

Correct Answer: Secondary [Syphilis](#)

Topic: Mycobacterial Infections

Q.10. A 38-year-old patient with hypopigmented nodular lesions with anesthesia overarm with ulnar nerve involvement underwent a biopsy and intradermal antigen test. Based on the image, which statement regarding the condition is most accurate?



1. Tuberculoid leprosy with a positive antigen test
2. Lepromatous leprosy with a positive antigen test
3. Erythema nodosum leprosum with a negative antigen test
4. Lepromatous leprosy with a negative antigen test

Correct Answer: Lepromatous [leprosy](#) with a negative antigen test

ENT

Topic: Larynx

Q.11. A singer is finding difficulty raising the pitch of her voice. On examination, her vocal cords were depressed and bowing. Which of the following muscles is involved?

1. Cricothyroid
2. Interarytenoid
3. Posterior cricoarytenoid
4. Lateral arytenoid

Correct Answer: Cricothyroid

EAR

Q.12. A 45-year-old woman is diagnosed with right vestibular neuronitis. What findings are expected during the head impulse test in this patient?

1. When the head is turned to the left, the eyeballs move to the left with Nystagmus.
2. When the head is turned to the left, the eyeballs move to the right with nystagmus.
3. When the head is turned to the right, the eyeballs move to the left with Nystagmus.
4. When the head is turned to the right, the eyeballs move to the right with nystagmus.

Correct Answer: When the head is turned to the right, the eyeballs move to the left with nystagmus.

Forensic Medicine

Topic: Forensic Thanatology

Q.13. In medicolegal examination, the accused 18-year-old male claims he is 16 years old. Which joint x-ray should be done?

1. Head & shoulder
2. Elbow and ankle
3. Knee and wrist
4. Elbow & hip

Correct Answer: Knee and wrist

Topic: Forensic Toxicology

Q.14. Police brought a person from the railway track with features of a dry, dilated pupil, dry skin, slurring of speech, and altered sensorium. The poisoning is?

1. Morphine
2. Cannabis
3. Datura
4. Alcohol

Correct Answer: Datura

Gynaecology & Obstetrics

Topic: Obstetrics

Q.15. The flexion point in a ventouse delivery is located at which of the following positions on the fetal head?

1. 3 cm posterior to the anterior fontanelle
2. 3 cm anterior to the posterior fontanelle
3. 6 cm anterior to the posterior fontanelle
4. Midway between the anterior and posterior fontanelle

Correct Answer: 3 cm anterior to the posterior fontanelle

Topic: Obstetrics

Q.16. Identify the instrument shown below



1. Kielland
2. Wrigley
3. Pipers
4. None of the above

Correct Answer: Pipers

Medicine

Neurology

Q.17. The patient is having a headache and confusion. A brain tumor diagnosis is made. Family history reveals brain and kidney tumors. Choose the correct option

1. Neurofibromatosis
2. Li fraumeni syndrome
3. VHL Syndrome
4. Churg strauss syndrome

Correct Answer: VHL syndrome

Q.18. A 62-year-old patient presents with left-sided arm and leg weakness, right-sided facial paralysis, and difficulty with horizontal eye movements. Based on the clinical presentation, which of the following syndromes is most consistent with these symptoms?

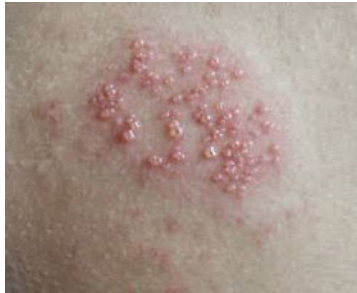1. Foville syndrome
2. Benedict's syndrome
3. Millard-Gubler syndrome
4. Wallenberg syndrome

Correct Answer: Millard-Gubler syndrome

Microbiology

Topic: Virology

Q.19. A patient presents with painful vesicles in the genital region. Identify the lesion shown in the image and choose the correct diagnosis



1. Herpes
2. Chancroid
3. Syphilis
4. Candidiasis

Correct Answer: [Herpes](#)

Topic: Parasitology

Q.20. A patient presents with perianal itching. A peripheral swab was taken, and the image below shows the findings. What is the most likely diagnosis?

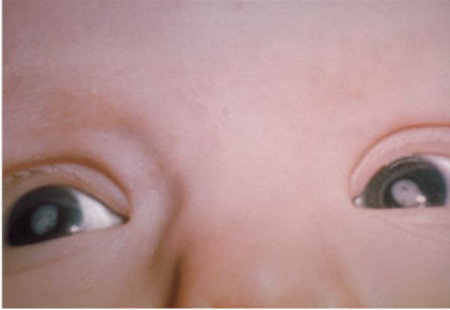1. H Nana
2. Ancylostoma
3. Enterobius vermicularis
4. Necator Americanus

Correct Answer: Enterobius vermicularis

Ophthalmology

Topic: Diseases of Lens

Q.21. A 2-month-old child is brought to the ophthalmology OPD with the following presentation. What is the ideal management?

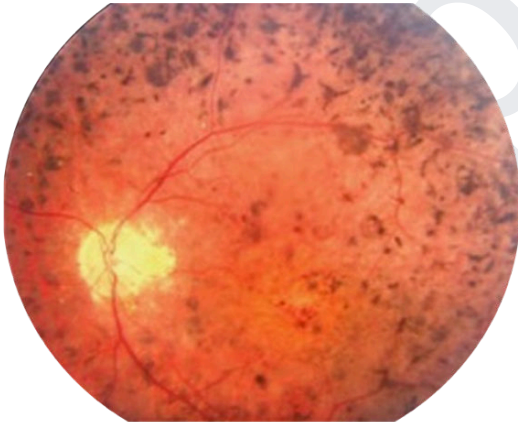


1. Medical management
2. Operate immediately
3. Surgery after 6 months
4. Surgery after 2 years

Correct Answer: Operate immediately

Topic: Retina

Q.22. A patient presents with a gradual loss of night vision and peripheral vision. What is the most likely diagnosis based on funduscopy findings?



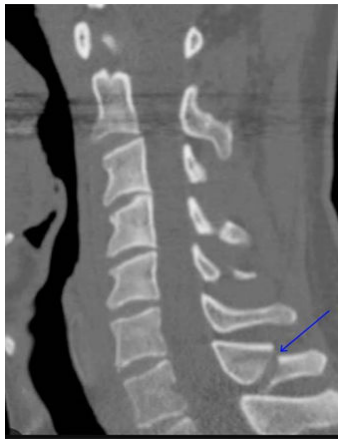1. Retinitis pigmentosa
2. Retinal hemorrhage
3. Diabetic retinopathy
4. Hypertensive retinopathy

Correct Answer: [Retinitis pigmentosa](#)

Orthopaedics

Topic: Spine + Pelvis + Lower Limb Traumatology

Q.23. A man presents with back pain following a road traffic accident. There was no history of neurological deficit. X-ray spine is done. What is the diagnosis?

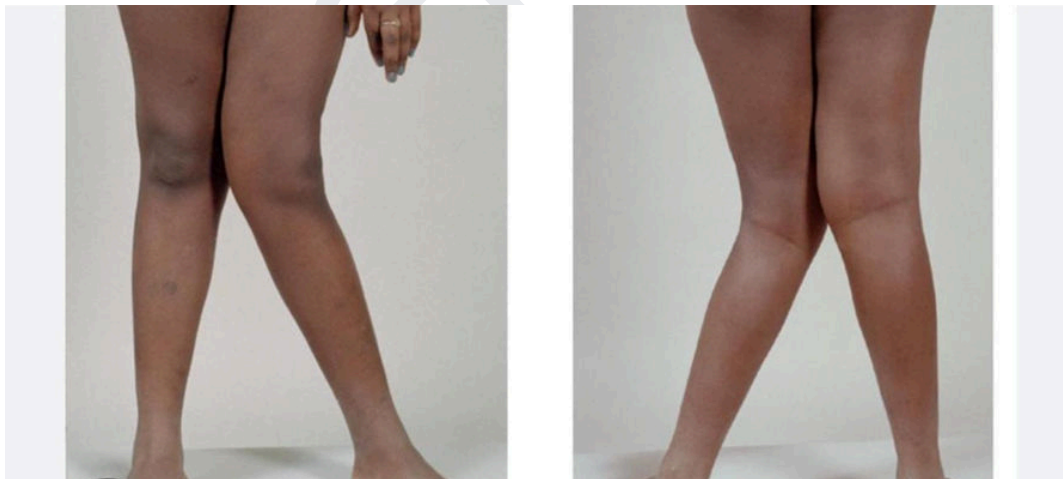

1. Spinous process fracture
2. Chance fracture
3. Fracture of base of vertebrae
4. Compressed fracture

Correct Answer: Spinous Process Fracture

Topic: Metabolic Disorders

Q.24. A child presents with growth failure. Biochemical analysis shows normal Ca^{2+} , normal PTH, reduced phosphate, and increased ALP. What is the diagnosis?



1. Nutritional rickets
2. Hypophosphatemic rickets
3. Type 1 VDDR

4. Type 2 VDDR

Correct Answer: Hypophosphatemic [Rickets](#)

Pathology

Topic: Hematology: White Blood Cells

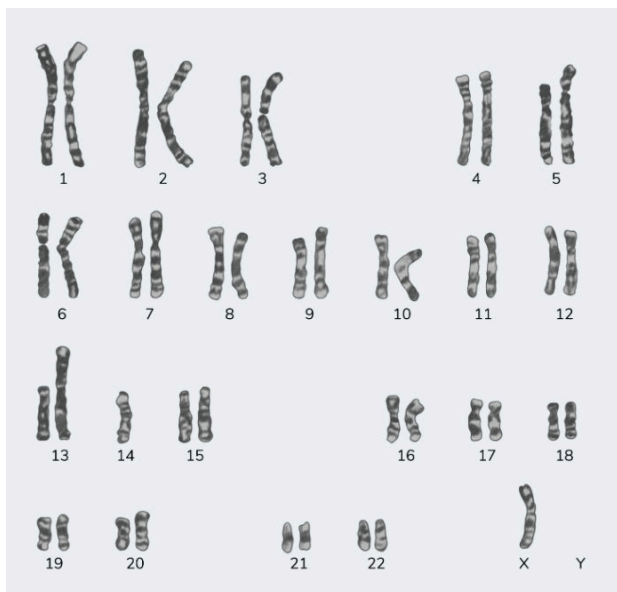
Q.25. A patient presents with fever, hepatosplenomegaly, abdominal pain, and WBC count $> 50,000/\text{mm}^3$. Which of the following genetic abnormalities is involved?

1. t(9;22)
2. del(1q)
3. t(15;17)
4. del 3q

Correct Answer: t(9;22)

Topic: Genetics

Q.26. A 23-year-old female with a height of 4 feet has a karyotype, as shown in the image below. Which of the following conditions is the most likely etiology?



1. Turner syndrome
2. [Klinefelter syndrome](#)
3. Mayer-Rokitansky-Küster-Hauser syndrome (MRKHS)
4. Edwards syndrome

Correct Answer: [Turner syndrome](#)

Pediatrics

Topic: Inborn Errors of Metabolism

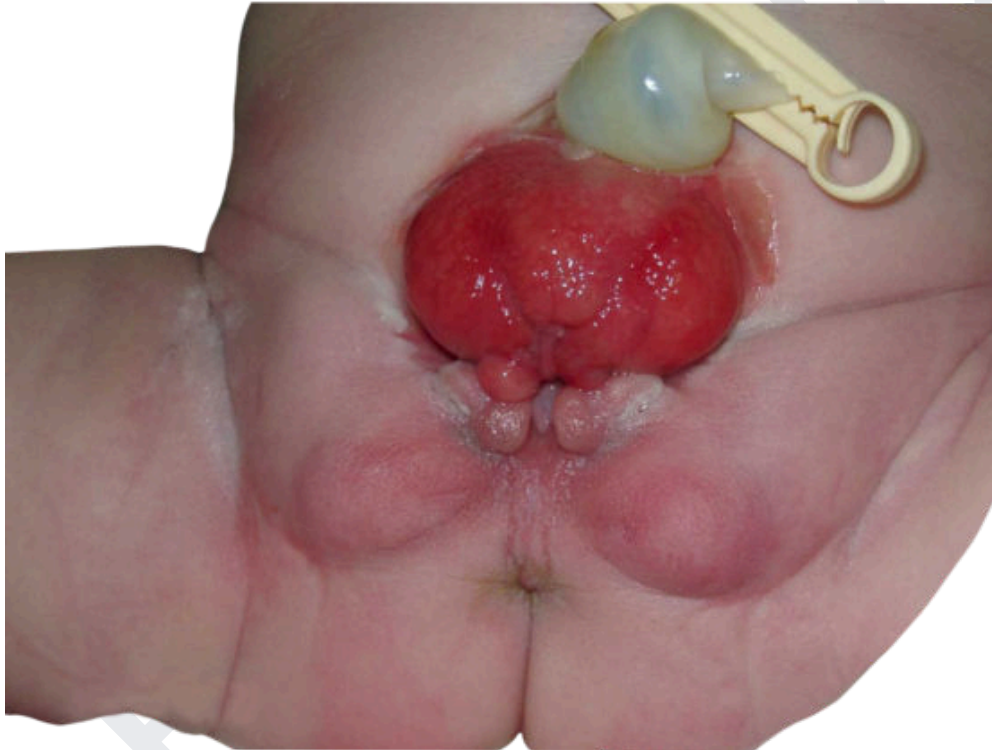
Q.27. An infant presents with vomiting after feeding. A Benedict's test was performed and returned positive for a non-glucose substance. Which of the following is the most likely diagnosis?

1. Galactosemia due to GAL-1-P uridyl transferase enzyme deficiency
2. Hereditary fructose intolerance due to aldolase B deficiency
3. Glucose-6-Phosphate dehydrogenase (G6PD) deficiency
4. Galactosemia due to galactokinase enzyme deficiency

Correct Answer: [Galactosemia](#) due to GAL-1-P uridyl transferase enzyme deficiency

Topic: Neonatology

Q.28. Which neonatal anomaly is depicted in the image?



1. Omphalocele
2. Gastroschisis
3. Patent vitello intestinal duct
4. Patent vitello intestinal duct

Correct Answer: [Exstrophy bladder](#)

Pharmacology

Topic: Respiratory Pharmacology

Q.29. Which of the following statements is incorrect regarding Samter's triad?

1. It is only triggered by aspirin.
2. Other NSAIDs with COX-1 blocking ability can also trigger symptoms.
3. It is characterized by asthma, nasal polyps, and aspirin sensitivity.
4. It involves overproduction of leukotrienes.

Correct Answer: It is only triggered by aspirin (Incorrect Statement)

Topic: Anticancer Drugs

Q.30. Aprepitant, a drug used to prevent late-onset chemotherapy-induced nausea and vomiting, acts through which of the following mechanisms?

1. NK-1 antagonist
2. NK-1 agonist
3. NK-3 antagonist
4. NK-2 antagonist

Correct Answer: NK-1 Antagonist

Physiology

Topic: Special Senses

Q.31. Sour taste is perceived by which receptors?

1. T1R1
2. T1R2
3. T1R3
4. TRPP3

Correct Answer: TRPP3

Topic: General Physiology

Q.32. Which ion is most responsible for the resting membrane potential (RMP)?

1. Potassium (K^+)
2. Calcium (Ca^{2+})
3. Sodium (Na^+)
4. Chloride (Cl^-)

Correct Answer: Potassium (K^+)

PSM

Topic: Communicable and Non-communicable Diseases

Q.33. A fruit farmer presents with fever, respiratory difficulties, and neurological complications. What is the most likely diagnosis?



1. Ebola
2. Meningitis
3. Nipah
4. Zika

Correct Answer: [Nipah](#)

Topic: Vaccines and Cold Chain

Q.34. Which of the following vaccines is kept at the lowest level?



1. OPV
2. DPT
3. Hep B
4. Rota

Correct Answer: OPV

Psychiatry

Topic: Substance-Related and Addictive Disorders

Q.35. Which drug is used in the maintenance phase of opioid withdrawal?

1. Buprenorphine
2. Disulfiram
3. Butorphanol
4. Clonidine

Correct Answer: Buprenorphine

Topic: Neurotic, Stress-Related and Somatoform Disorders

Q.36. A 45-year-old woman presents with a long-standing history of “feeling tensed” along with an upset stomach, diarrhea, and heartburn. She mentions that her family members also experience similar symptoms. Which of the following symptoms is most likely to be observed in this patient?

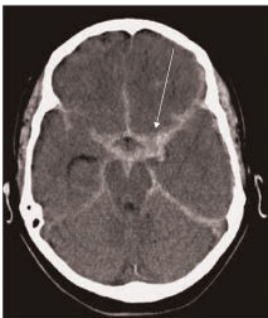1. Neologisms
2. Tingling at extremities
3. Hallucinations
4. Idea of reference

Correct Answer: Tingling at extremities

Radiology

Topic: Head & Neck Imaging

Q.37. A 40-year-old female patient complains of a persistent headache. A CT scan of the head was performed, as shown below. What is the most accurate diagnosis?

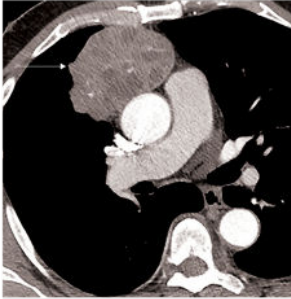


1. Subarachnoid hemorrhage (SAH)
2. Epidural hemorrhage
3. Subdural hemorrhage
4. Intraparenchymal hemorrhage

Correct Answer: [Subarachnoid hemorrhage \(SAH\)](#)

Topic: Thoracic Radiology

Q.38. A 45-year-old patient presents with ptosis and muscle weakness that improves with rest. She also complains of dysphagia and has engorged veins in her thorax. Based on the CT scan image provided, what is the most likely diagnosis?



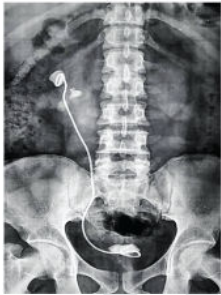1. Thymoma
2. Pancoast tumor
3. Adenocarcinoma
4. Small cell lung cancer

Correct Answer: Thymoma

Surgery

Topic: Urology

Q.39. What instrument is used to insert this tube?



1. Nephroscope
2. Cysto urethroscope
3. Ureteroscope
4. Endoscope

Correct Answer: Cysto-urethroscope

Topic: General Surgery

Q.40. What is the ideal pressure setting for vacuum-assisted closure (VAC) therapy?

1. -125 mm Hg
2. 60 to 80 mm Hg
3. 130 mm Hg



4. 80 to 100 mm Hg

Correct Answer: 125 mm Hg

If you wish to access the detailed explanations for the correct and incorrect options of these questions, download the PrepLadder app now.

Download PrepLadder's [NEET PG app for Android](#)

Download PrepLadder's [NEET PG app for iOS](#)

PrepLadder